

Combination therapy with BOTOX™ and fillers: the new rejuvenation paradigm

KIERSTEN R. COLEMAN* & JEAN CARRUTHERS*

**Department of Dermatology, Louisiana State University Health Sciences Center, New Orleans, Louisiana and *Department of Ophthalmology, University of British Columbia*

ABSTRACT: Until relatively recently, restoration of appearance by replacement of lost facial volume and muscular relaxation has been an illusory goal. With advances in the commercial availability of newer filling agents and a better understanding of the clinical esthetic effects of botulinum toxin A, remarkably sophisticated and refined results can now be achieved by using these noninvasive techniques. The combined use of BTX-A and filling agents, such as collagen and hyaluronic acid, can restore facial appearance by the dual mechanisms of reflation and relaxation. In addition, their combined use appears to increase the longevity of tissue dwell time of the filling agent. Current practices now strive to correct wrinkles by restoring volume and also relaxing the pull of muscles that create negative facial expressions such as glabellar folds, mouth frown, crow's feet, horizontal forehead lines, and perioral and cervical rhytides. As with any of the new technological innovations currently available, understanding of the differing properties of the agents used and education in optimal technique is essential to clinical and esthetic success.

KEYWORDS: BOTOX, botulinum toxin A, collagen, fillers, hyaluronic acid

Introduction

Facial volume depletion and deepening lines of facial expression as a part of normal facial aging has been appreciated by both physicians and artists over many centuries. Philosophies and practices in delaying or correcting the effects of aging have changed drastically over the last few decades. Traditional brow and face-lifts alone often produce a too tight, gaunt, or an obvious “done” look. Current practices now strive to correct wrinkles by restoring volume and also relaxing the pull of muscles that create negative facial expressions such as glabellar folds, mouth frown, crow's feet, horizontal forehead lines, and perioral and cervical rhytides.

Until relatively recently, however, restoration of appearance by replacement of lost facial volume

and muscular relaxation has been an illusory goal. With recent advances in the commercial availability of newer filling agents and a better understanding of the clinical esthetic effects of botulinum toxin A (BTX-A), remarkably sophisticated and refined results can now be achieved by using these noninvasive techniques. The combined use of BTX-A and filling agents can restore facial appearance by the dual mechanisms of reflation and relaxation. In addition, their combined use appears to increase the longevity of tissue dwell time of the filling agent.

Most commonly used biodegradable fillers: collagen and hyaluronans

Collagens

The use of injectable substances in facial augmentation spans over a century. In 1893, Neuber successfully transplanted fat taken from the arm

Address correspondence and reprint requests to:
Jean Carruthers, 740–943 West Broadway, Vancouver, BC
V5Z4E1 Canada, or e-mail: drjean@carruthers.net.

to the face for the correction of depressed facial scars (1,2). Between 1900 and 1935, paraffins were used as dermal fillers to correct facial deformities and elevate furrows and depressions. The formation of foreign body granulomas and, in some cases subsequent facial disfigurement, was unfortunate complications that led to the end of paraffin use (3). Fluid silicones were first used in the 1950s but their use was later declared illegal by the U.S. Food and Drug Administration (FDA) because of adulterated preparations and indiscriminate use among some physicians. Injectable collagen has been in use since 1977. In 1981 the bovine collagen Zyderm I received FDA approval for the correction of scars and wrinkles. This marked the first time an injectable nonautologous, xenogenic substance became FDA-approved for soft-tissue augmentation. Zyderm II received FDA approval shortly thereafter, and approval for Zyplast came in 1985 (4). In 2003 the hyaluronic acid gel, Restylane™, was approved for use in augmentation of nasolabial folds. Currently, bovine collagen and Restylane™ represent the most widely used dermal fillers.

Collagen is the most abundant protein in the human body. It provides skin resilience, durability, support, and helps maintain structure (5). The normal human dermis contains roughly 80% type I collagen and 20% type III collagen. Bovine collagen was first extracted from calfskin in 1958. By warming a solution of this collagen to body temperature, a solid gel was formed. In the 1960s, the antigenicity of the bovine collagen molecules was found to be significantly reduced by the removal of nonhelical amino and carboxyl terminal telopeptides (4). From this research emerged commercial, injectable bovine collagens. All are sterile, purified, and reconstituted combinations of fibrillar bovine types I and III collagens, taken from the skin of a closed American herd. Zyderm I is a suspension of 3.5% bovine collagen (95% type I collagen and 5% type III) in phosphate-buffered physiologic saline with 0.3% lidocaine. The highly antigenic telopeptide ends are removed by pepsin digestion, without interruption of the natural helical structure of the collagen molecule. Zyderm II has a higher concentration of collagen (6.5%) but is otherwise identical to Zyderm I. Zyplast contains the same concentration of bovine collagen as Zyderm I and is also in a suspension with physiologic saline and 0.3% lidocaine. This collagen, however, is lightly cross-linked by the addition of 0.0075% glutaraldehyde. A lattice is formed by the covalent bridging between 10% of available lysine residues of the collagen molecule.

Because of these intermolecular, intramolecular, and interfibril bridges, Zyplast is more resistant to proteolytic digestion and is less immunogenic (4,6).

All three forms of bovine collagen are packaged in preloaded syringes. Storage in a refrigerator (4°C) ensures that the dispersed collagen fibrils remain fluid and small, allowing for easier passage through small-gauge needles. Once injected into the dermis, human body temperature causes the collagen to consolidate into a gel, as was demonstrated years ago *in vitro* (4). Recognized as a foreign body, collagen is degraded by the immune system over a period of several months (7). Zyderm I has been described as the most versatile, most technique-sensitive, and most forgiving of the preparations. Both Zyderm I and II contain collagen in the form of microfibrils and have good flow characteristics. The more highly concentrated Zyderm II requires greater mechanical force to inject. Injection of both substances is targeted to the papillary dermis. Soft, distensible, and superficial rhytides respond best to Zyderm I and II. They have been shown to improve horizontal forehead lines, glabellar lines, periorbital rhytides, shallow nasolabial folds, fine perioral lines, and superficial acne scars. The cross-linked structure and lack of microfibrils in Zyplast produces a thicker substance with less flow. It is injected into the reticular dermis where it functions to correct deep rhytides (4). It is also reported to last longer than either Zyderm preparation and demonstrates less immunogenicity (7). Zyplast works best to correct deeper nasolabial lines, deep acne scars, and reshaping of the vermilion border for lip enhancement. For rhytides with deep and superficial components, a layering technique may be used with Zyderm injected over areas corrected more deeply with Zyplast (8). Correction is temporary and requires periodic maintenance (6). Longevity of correction is dependent upon multiple factors including the patient's local immune response, the location and depth of the depression, and the level of mobility of the surrounding tissue (3,7).

Adverse reactions to bovine collagen may be divided into hypersensitive or allergic and non-hypersensitive reactions. Because of the 3–5% allergic reaction rate, skin testing with the collagen material is required prior to treatment (7). Numerous methods of skin testing are reported in the literature, but the consensus is to perform two separate skin tests (3). Collagen is placed intradermally on the volar aspect of the forearm. This area is evaluated at both 48–72 hours and 4 weeks after

placement for erythema, induration, swelling, tenderness, or pruritus. A second skin test is recommended either on the contralateral forearm or on the face around the hairline. This can be performed 2 weeks after the initial test with a final reading 2 weeks later, or it may be placed at the 4-week follow-up visit with a final reading in another 2 weeks. Double testing greatly reduces the likelihood of a treatment-related hypersensitivity response. If an allergic reaction does occur, it is usually mild, manifesting with erythema and edema. Mild systemic symptoms and serum sickness-like illnesses have infrequently been reported (3,6). Adverse reactions as a result of a local granulomatous reaction have been correlated with circulating antibodies against bovine collagen. Abscess or cyst formation is a rare reactive response that may occur at any time after collagen injection. Antihistamines, topical, or intralesional steroids and incision and drainage are used to treat the various complications described in previous discussions (3).

Nonhypersensitive reactions include bruising, erythema, temporary overcorrection, and edema. Rare adverse events include the reactivation of herpetic or bacterial infections, recurrent intermittent swelling, local skin necrosis, and loss of vision as a result of collagen emboli to the ophthalmic artery (8). Contraindications to the use of bovine collagen include active infection or inflammation, history of anaphylactoid reaction or previous allergy to the collagen, history of autoimmune disease or immunosuppression, and lidocaine hypersensitivity (9).

In 2003, CosmoDerm and CosmoPlast™ (human bioengineered collagen-derived from tissue culture of the fibroblasts from baby foreskin) received FDA approval. This was the first instance that a human-derived product from live tissue-cultured human cells became commercially available. Part of the significance was the fact that now, no skin test was required.

Hyaluronans

Hyaluronic acid is a ubiquitous component of all mammalian connective tissue. It is found in skin, the vitreous body of the eye, joints, and muscles. It resides in the extracellular space where it functions in stabilization of structure and as a cell-protective molecule. In the dermis, hyaluronic acid functions to bind water and contributes to skin turgor and elasticity. On a molecular level, hyaluronic acid is a long dimeric polysaccharide consisting of alternating N-acetyl glucosamine

and glucuronic acid residues (9). The matrices of the molecule are highly viscoelastic and provide a high level of hydration. In fact, the water content in skin seems to highly correlate with the dermal levels of hyaluronic acid. Hyaluronic acid metabolism and content changes as one ages, suggesting a correlation between intercellular hyaluronic acid and youthful skin (10). Because it is identical among many species and is produced by many cells, there is no antigenicity associated and the incidence of adverse reactions is low (3). Hyaluronic acid is injected into the dermis where the body's own substance has been depleted. Once in the skin, it combines with the skin's remaining hyaluronic acid and creates volume. It is later broken down within the dermis and eliminated through the lymphatics and by hepatic metabolism (4).

Hylan B is a commercially produced hylan gel that is available for use in Canada and Europe. It is composed of cross-linked hyaluronan polysaccharide chains with high molecular weight. Cross-linking forms a hydrophilic, insoluble polymer that has an increased life in tissue (11). Hylan B is produced from rooster combs. Erythema, ecchymoses, acne, and hypersensitivity-like reactions have been reported. Because of this, some physicians perform skin tests with the product prior to treatment (4).

Restylane™ is currently FDA-approved for the treatment of nasolabial rhytides. It is a partially cross-linked hyaluronic acid product that is produced by fermentation from cultured *Streptococcus* bacteria. Its production utilizes NASHA (nonanimal stabilized hyaluronic acid) technology (10). It is more highly concentrated than Hylan B, but has a lower molecular weight. The half-life of Restylane™ is approximately 1 year. Its degradation is isovolumic: it retains most of its initial filler volume throughout the degradation phase. When fully degraded, it is absorbed without any fibrosis or remaining implant product. Metabolism by-products are water and carbon dioxide. Because it is a natural component of human tissue and is produced by bacteria, the reactivity profile of Restylane™ is low. Injection-related reactions include bruising, pain, erythema, edema, itching, and discoloration overlying the treatment area (3). There have, however, been reports of hypersensitivity reactions ranging from 0.0005% to 0.42% (10). In rare instances, the material has reportedly perforated and extruded through the skin (4). Two cases of embolization of the dorsal nasal artery caused by Restylane™ injection have been reported in the literature (12,13). Currently,

Restylane™ is the most widely used dermal filler in North America. Two other related filling agents (Perlane™ and Restylane Touch™) currently await approval by the FDA although they are in current use in Europe and Canada.

Botulinum toxin-A

The clinical possibilities of botulinum toxin were first investigated in the 1920s. In the late 1970s, Dr Ed Maumenee suggested to Dr Alan Scott that BTX-A might work as a muscle-paralytic agent. In a remarkable comparison trial in which BTX-A, diisopropyl fluorophosphate, cobra venom, and absolute alcohol were injected into the extraocular muscles of macaque monkeys, Scott demonstrated the clear superiority of the BTX-A in effective muscle realignment without damage to the monkey's general health. In 1980, Scott demonstrated the first therapeutic use in humans in the treatment of strabismus (misaligned eyes) in which a crystalline form of the toxin was injected intramuscularly into the appropriate extraocular muscle, thus transiently denervating it and resulting in ocular realignment. This provided an exciting alternative to traditional strabismus surgery (14).

Over the last 25 years, many clinical indications for botulinum toxin have been discovered. It has been used in the treatment of blepharospasm, hemifacial spasm, cervical dystonia, neuropathic pain, migraine headaches, and hyperhidrosis (15). It may even play a role in the treatment of obesity (16). Common to many of the mentioned disorders is a component of undesired muscle hyperactivity. Facial rhytides similarly have a component of muscle activity as they are created and exacerbated by movement from facial expression. The cosmetic possibilities of botulinum emerged in 1987 when one of the authors (JDAC) noted a softening of glabellar lines in patients whose blepharospasm strabismus was treated with botulinum toxin (17). In 1992, Carruthers and Carruthers reported on the safe and successful treatment of glabellar frown lines with botulinum toxin (18). Ten years later, the FDA approved the use of botulinum toxin for the treatment of glabellar rhytides. Commonly known as BOTOX, BTX-A has proven to be a successful, efficacious, and safe treatment modality for unwanted wrinkles on the face and neck (19).

Botulinum is a polypeptide neurotoxin derived from the bacteria, *Clostridium botulinum*. Of the eight distinct serotypes, type A is the most potent and is commercially available as BOTOX (20). It is

a 150-kDa double chain polypeptide composed of a heavy and light chains connected by disulfide bonds. The heavy chain promotes the internalization and activation of the light chain. The light chain is a zinc-dependent metalloproteinase that cleaves SNAP-25, a 25-kDa synaptosome-associated protein. SNAP-25 is involved in the docking and release of acetylcholine from vesicles situated within the neurons. Thus, BOTOX acts at the level of the presynaptic neuronal endplate where it prevents acetylcholine release. This does not affect the production of the neurotransmitter acetylcholine and the effect is reversible. The toxin is unable to penetrate the blood-brain barrier and systemic absorption is minimal to nil (15,20,21). Intramuscular injection of BOTOX causes a dose-dependent temporary chemodenervation of targeted striated muscles, causing weakness or partial paralysis. Botulinum is measured in biological units (U) defined as the median lethal dose when injected into the peritoneum of a standard mouse model (20). Response to BOTOX is related to the dose, injection technique, and mass or strength of the muscle treated. There are reports of effects evident as early as 24–48 h after injection; however, full effect typically takes 3–10 days. Duration of effect may be expected to last for 3–6 months. Patients who have history of prior treatments may notice that effects begin to last longer. In some instances, the duration of effect increases as the number of treatment session increases. It is debated whether or not muscle atrophy contributes to this phenomenon (22). Furthermore, a higher proportion of patients respond to BOTOX injections after multiple treatments (23).

Although BOTOX is a safe treatment for most, there are some contraindications and associated complications. Reported contraindications include the use of quinine, calcium channel blockers, penicillamine, or aminoglycoside antibiotics. BOTOX is pregnancy category C: women who are breastfeeding, pregnant, or attempting pregnancy should not have treatment with BOTOX. Those with neuromuscular diseases like myasthenia gravis, Eaton-Lambert syndrome, or peripheral neuropathy should not be treated. BOTOX should never be injected into an area of active infection (9,20,22). As the number of areas now treated with BOTOX increases, so does the number of complications. Most adverse effects are minor and resolve spontaneously. These include pain on injection, bruising, headache, nausea, erythema, and edema. Facial asymmetry, eyebrow ptosis, and accentuation of the lower eyelid fat pad are

minor unwanted cosmetic effects. Upper eyelid ptosis, diplopia, paralysis of the lateral rectus oculi muscle, ectropion, dry eyes, incompetence of the orbicularis oris, dysphagia, and severe headaches are more severe complications reported in the literature. Most of these adverse effects are the result of improper injection technique, location, and/or too strong a dose. Like the desired cosmetic effects of BOTOX, these effects are transient and resolve spontaneously (24). The formation of neutralizing antibodies to BOTOX leads to the ineffectiveness of treatments. Antibody formation is both dose and frequency dependent. Doses greater than 200 units and treatment interval time of less than 1 month have more potential for immunogenicity. Thus, it is recommended that physicians use the lowest efficacious dose and space treatments at least 3 months apart (20).

The combination of fillers and BOTOX

The phenomenon of aging is a complicated multifactorial process, not yet fully understood. On the face, aging manifests as wrinkles, furrows, sagging, dyspigmentation, and changes in skin texture. The forces of aging include gravity, photodamage, soft tissue maturation, skeletal remodeling, and muscle activity. Commonly in the thirties, wrinkles and fine lines develop around the eyes and mouth and the upper and lower eyelids begin to sag. In the fifties and sixties, the tip of the nose drops, the jawline begins to sag, and skin on the neck becomes lax and folds (5). Volume loss and muscular hyperactivity are two major components in the aging process that together contribute to the formation of wrinkles. Intuitively, the treatment of both processes produces a more natural and refined outcome. With dermal fillers, volume is restored. With BOTOX, muscle movement is decreased. Each targets a specific property of facial aging. Thus, the combination of BOTOX with soft tissue augmentation is a highly effective dual-step approach in reshaping and contouring the face (25).

Dermal and subcutaneous filler substances like collagen and hyaluronic acid products are used to recreate a more rounded youthful-appearing face. These products replenish the collagen protein scaffolding and restore moisture (26). They work as tissue expanders, thicken the dermis, and as a result plump unwanted furrows. They can also be used to increase symmetry and balance facial proportions. Commonly, soft tissue augmentation is used throughout the face to provide support,

raise eyebrows, reshape the nose, lift the nasal tip, soften nasolabial folds, restore volume in the oral commissures, fill in hollowed-out cheeks, heighten cheekbones, and contour the jawline (5).

Facial wrinkles have both a dynamic and static component. Dynamic rhytides are produced by muscle contraction and are a natural part of facial animation, portraying emotion. These are most evident as the furrowing of the brow and glabella, elevation of the forehead in surprise or delight, “crow’s feet” that form by squinting, and “smile lines” or nasolabial folds. It is well known that the dynamic nature of wrinkles is safely and effectively counteracted with BOTOX. By weakening or even paralyzing the muscles of facial expression, the wrinkles that form perpendicular to the underlying muscles are inhibited (27). Static rhytides are produced by exogenous forces such as gravity, the sun, sleeping, and smoking (4). Over time, the “wrinkles” of facial expression may begin to be present even at rest. It is hypothesized that constant motion may cause the formation of subdermal fibrotic connections and muscular fascial contractions, thus producing static rhytides (7). By combining BOTOX and collagen fillers, one is able to correct both the dynamic and static components of rhytides.

Clinical areas of common combination BOTOX and filler treatments

- resting glabellar folds;
- brow height adjustment;
- horizontal forehead lines;
- nasojugal folds;
- resetting facial contours: zygomatic region;
- resetting facial contours: perioral region;
- cervical region.

Resting glabellar folds

In younger subjects, the glabellar frown lines really only appear with dynamic action of the corrugator superciliaris, procerus, depressor supercillii, and orbicularis oculi. Monotherapy with BTX-A alone is usually very effective (FIG. 1a,b) (27–29).

With increasing photodamage, the glabellar lines become etched in at rest. Treatment with BTX-A alone will not give the subject a positive esthetic result because they still see the resting

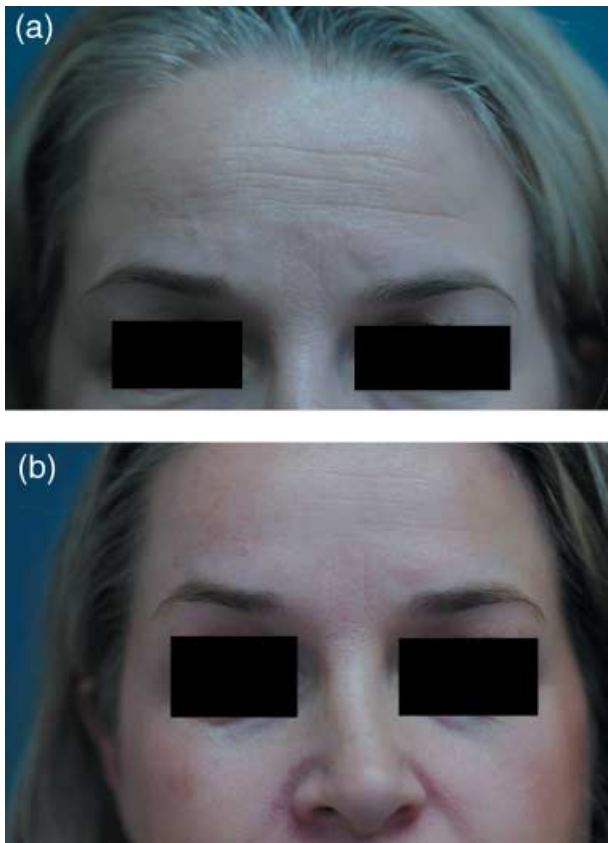


FIG. 1. (a) Resting glabella before BOTOX chemodenervation monotherapy to the glabellar region post.

fold despite the fact they cannot dynamically frown.

Combining BTX-A with intradermal fillers such as hyaluronan will not only give an immediate resting result but will also allow the filler to last approximately twice as long (FIG. 2a,b,c) (30,31).

Brow lift

The brows appear simple, but actually are extremely important because of their complex messaging. Brows convey not only emotional state, but also gender, level of authority, and standard of beauty.

Brow ptosis is a common concomitant of aging and often creates an inadvertent hostile negative impression in women and if more severe, also in men. BOTOX alone in a younger subject will raise the ptotic brow 1–2 mm (FIG. 3a,b) (32). Interestingly, mild brow ptosis is normal in men and in them gives an impression of leadership and power. Severe brow ptosis in men, as it is

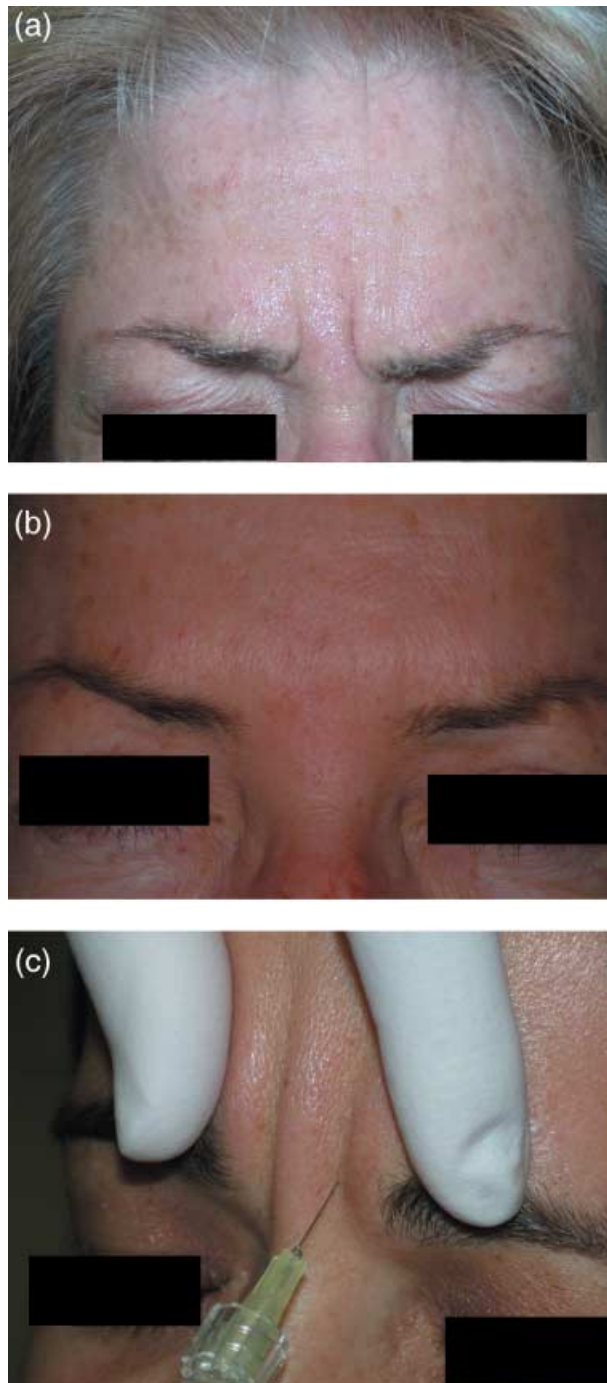


FIG. 2. (a) Dynamic glabellar frown before simultaneous BOTOX and NASHA injection. (b) Attempted glabellar frown after simultaneous BOTOX and NASHA injection. (c) Injection technique for deep intradermal injection of NASHA into the depth of the glabellar fold.

in women, is also read negatively by the public, primarily as anger.

Often in women there is differential descent of the lateral brow causing a sad disappointed expression. Injecting BOTOX along the brow to

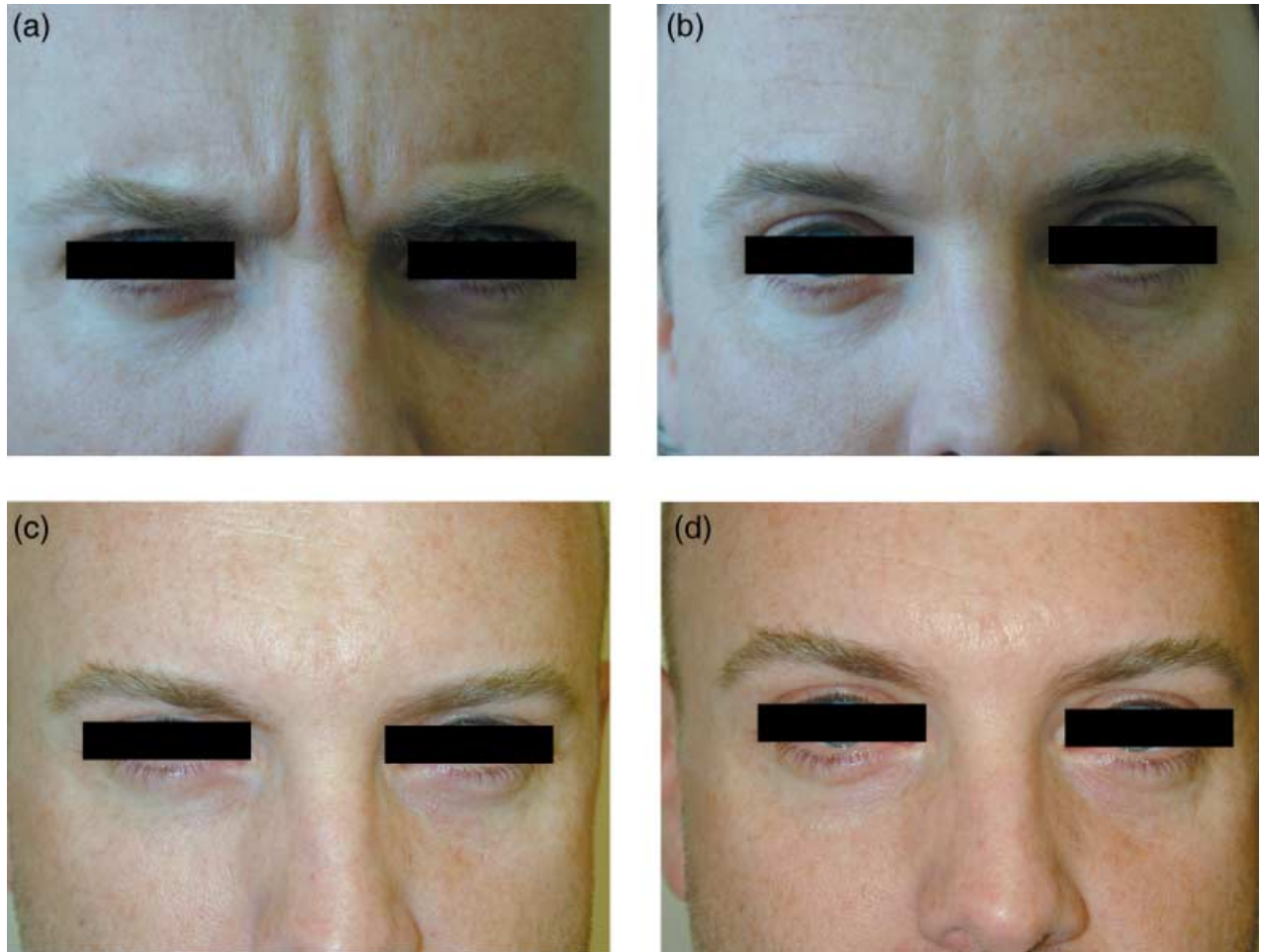


FIG. 3. (a) Frowning pretreatment. (b) At rest pretreatment. (c) Attempted frown post-treatment. (d) At rest post-treatment showing brow elevation.

the tail at the junction with the temporal fusion line will help lift the lateral brow and restore the arch (32). Simultaneously injecting filler into the lateral brow fat pad will exaggerate the lateral brow lift, and will give a youthful anterior projection to the lateral brow contour (FIG. 4a,b) (33).

Horizontal forehead lines

Horizontal forehead lines usually start to become evident when there is early brow ptosis. Most men are not too distressed until they become relatively deep. Most women view them as a distinctly masculinizing feature. Treatment with BOTOX should only be undertaken when the brow depressor musculature has been cotreated in order to avoid brow ptosis. If in the opinion of the physician, the brows are somewhat low, especially in a middle-aged female subject, the brow elevator

treatment should be postponed until the brow depressor treatment is working (34).

Treating horizontal forehead lines with filler can be problematic if the injector is not experienced and leaves residual beads of filler in the superficial dermis. We feel that BOTOX treatment is esthetically superior on its own rather than using the combination in this area (FIG. 5a,b).

Nasojugal folds/hypertrophic orbicularis

The nasojugal fold may be just visible in childhood and in young adulthood. With loss of facial volume with the aging process, the descent of the globe within the orbit supported on Lockwood's ligament and the descent of the malar fat pad, the nasojugal fold becomes deeper, and the skin overlying it appears dark because of the shadowing cast by the medial orbital fat pad above the bone

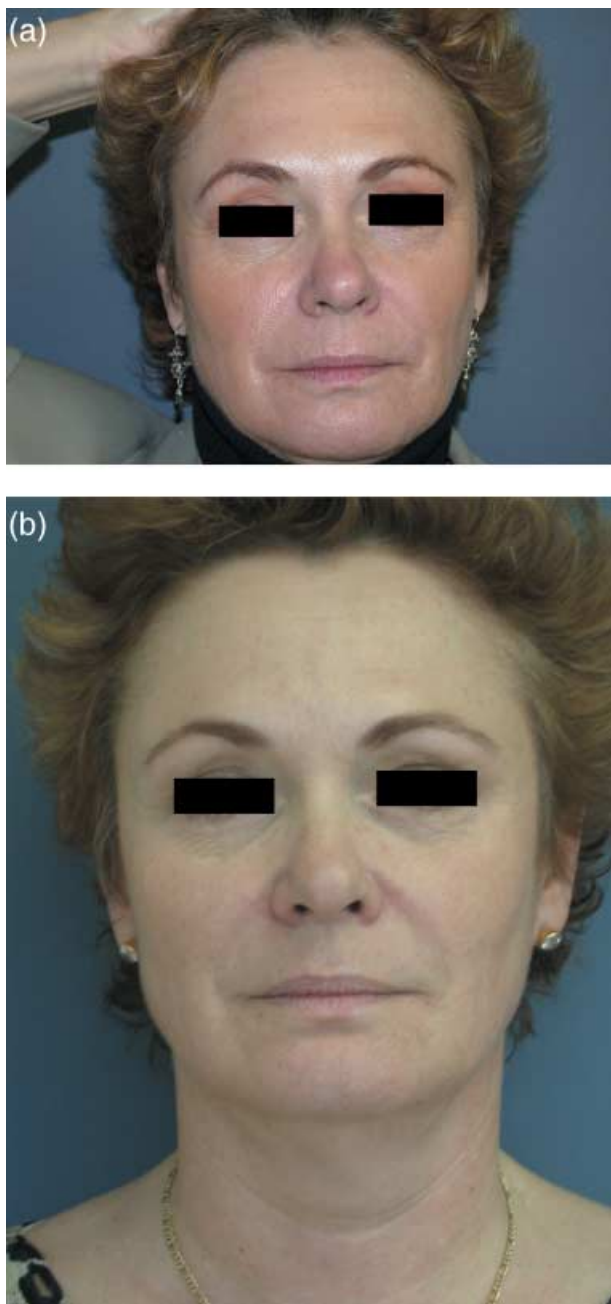

FIG. 4. (a) Lateral brow ptosis pretreatment. (b) Lateral brow ptosis post-treatment with BOTOX and NASHA to reflate the lateral brow fat pads.

of the arcus marginalis of the orbit below and the fullness of the malar fat pad inferiorly. In both men and women, the deep nasojugal fold gives an appearance of tiredness (FIG. 6a,b) (35).

In most individuals, the lateral orbital margin is still nicely draped with malar fat. In some thinner and older subjects, the lateral bony margin also is displayed and gives the subject a prematurely skeletonized appearance.

Years ago, the treatment was surgical – to remove the medial orbital fat above the nasojugal fold by a transconjunctival blepharoplasty or to elevate the malar fat using a mid face lifting procedure. Now the nasojugal fold and the lateral arcus marginalis can be reflatened with filler such as Restylane™ and Cosmoplast™.

For those subjects who have in addition the hypertrophic orbicularis with a normal snap test, the lower lid contour can be further improved by injecting 2 units of BOTOX in the mid pupillary line 2–3 mm below the inferior ciliary margin (FIG. 7a,b) (36,37).

Resetting facial contours: zygomatic region

A young adult woman has a more heart-shaped face than a young man. In part this is because the brow is less full and the eyes are more prominent than in a man who has bigger supraorbital ridges and more deeply set eyes. The man's maxilla, muscles of mastication, and mandible are also sturdier than in a woman of similar age. Recent research has shown that the bones of the face are not only shrinking slightly as we age, but also human anthropological studies appear show a 1–3% decrease in the size of our facial bony skeleton every 1000 years. Possibly this is the result of our more refined food requiring less work to process it for digestion.

A flatter zygoma used to be treated with surgical implants made of inert materials such as Goretex. This was an invasive process requiring some downtime for the subject. Now we suggest subcutaneous placement of the filling agent inferior and lateral to the lateral canthus. This nicely plumps up the region and the effect lasts longer than in the perioral region as there is so much less movement. We usually recommend BOTOX to the crow's feet region simultaneously. The combination lifts and redrapes the upper cheek skin restoring the “apple appearance” – depending on how much filler is desired by the subject (FIG. 8a,b) (33).

Resetting facial contours: perioral region

If the brows are the center of the cosmetic facial universe, the perioral region is the true heart of the face.

The lips are the center of the perioral frame. Although most subjects initially request treatment

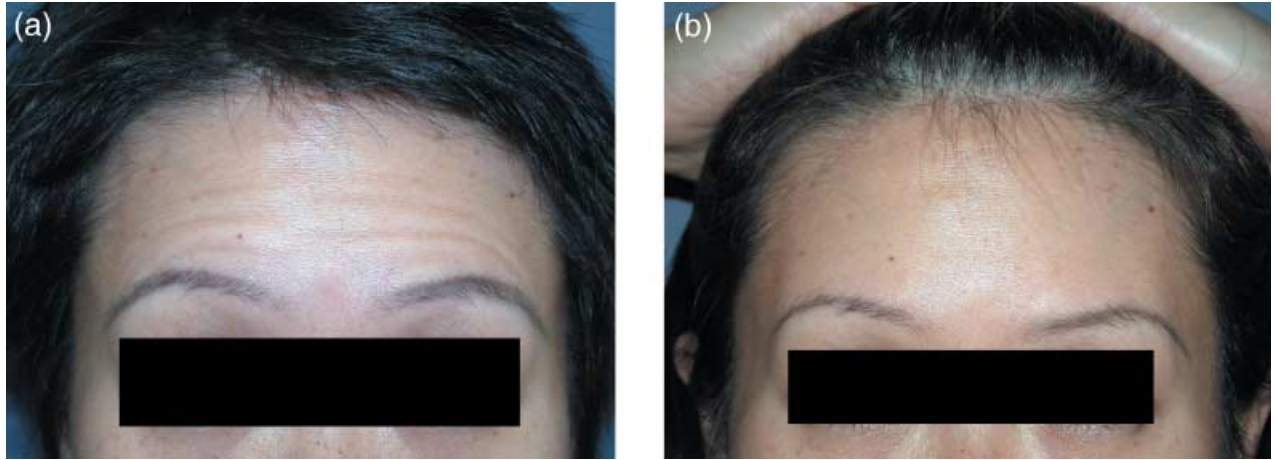


FIG. 5. (a) Horizontal forehead lines prior to cotreatment of brow depressors and frontalis to maintain normal brow height. (b) Horizontal forehead lines after BOTOX treatment of the brow depressors and elevator.

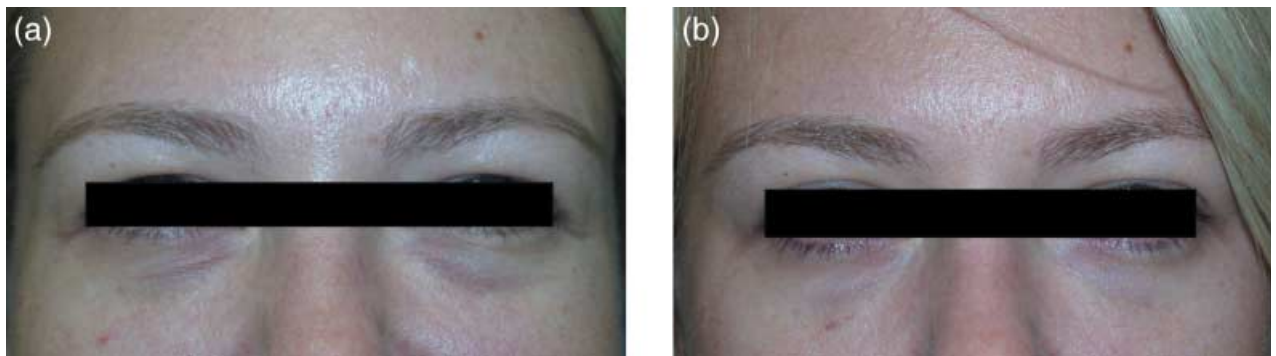


FIG. 6. (a) Deep nasojugal folds prior to treatment with submuscular human collagen. (b) Postnasojugal augmentation with human collagen injection.

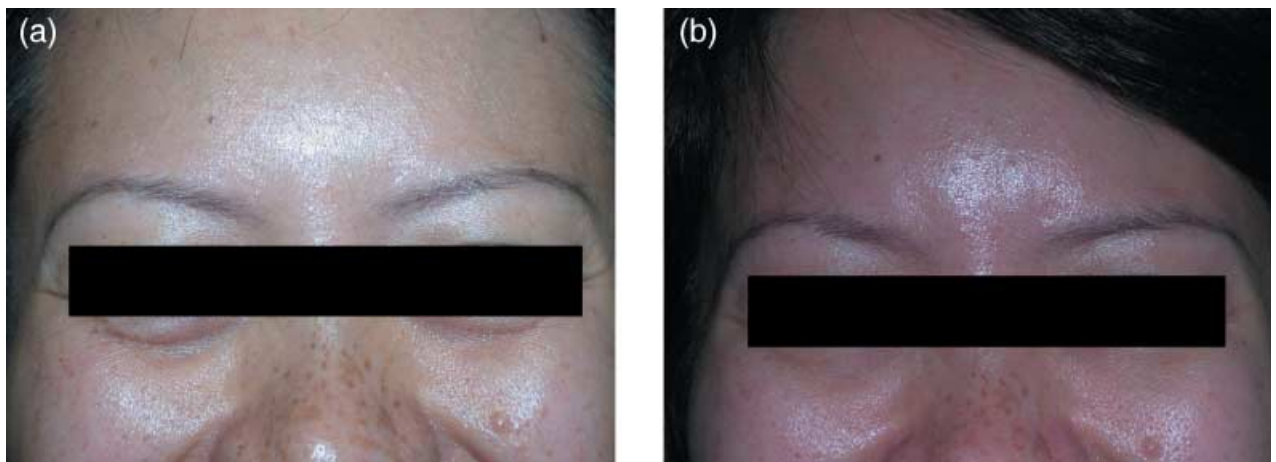


FIG. 7. (a) Pre-BTX-A treatment of the hypertrophic pretarsal orbicularis of the lower eyelid. (b) Post-treatment with BTX-A. Note the wider palpebral aperture on full smile.

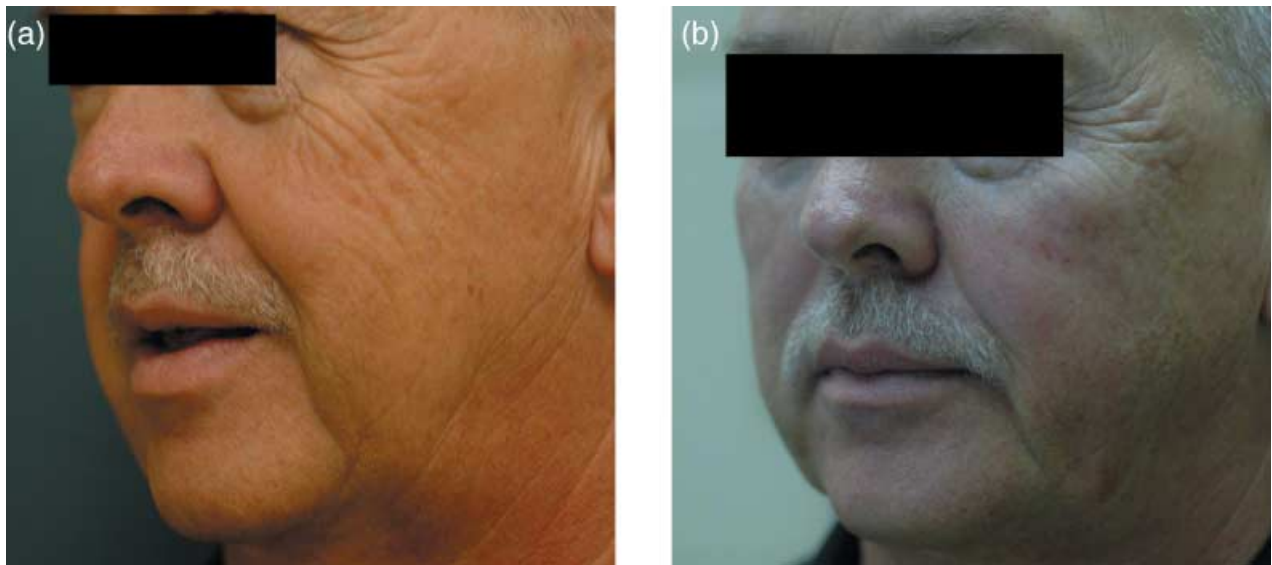


FIG. 8. (a) Deep elongated crows' feet treated with simultaneous BTX-A and Radiesse. (b) Post-treatment appearance with combination treatment with BTX-A and Radiesse.

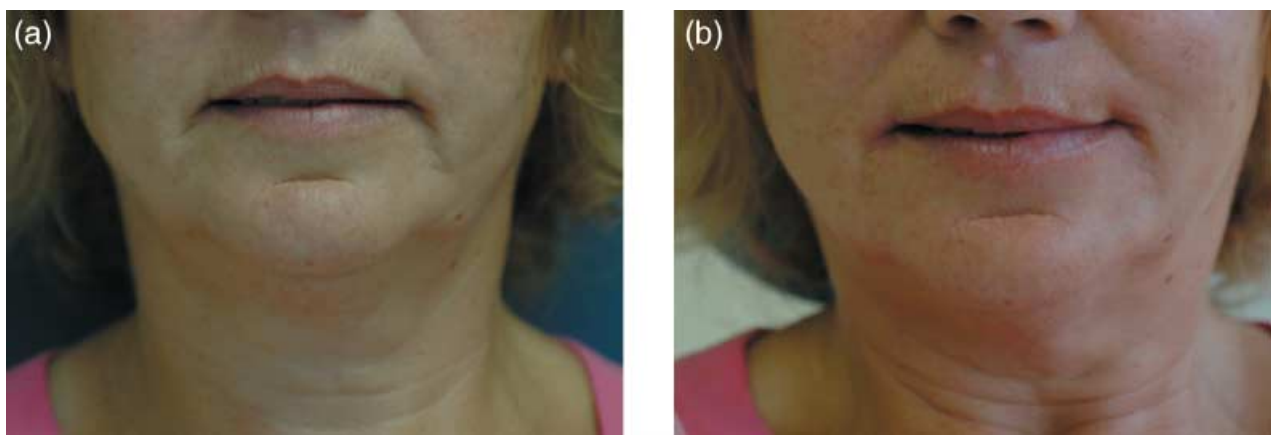


FIG. 9. (a) Deep melomental folds and mouth frown prior to BTX-A to depressor anguli oris and Radiesse to melomental folds. (b) Postcombined treatment with BTX-A and long-lasting volumizing filler.

for the lips alone, further education of the individual clarifies that if the perioral region is not treated, we will not be able to realize the full esthetic potential of the entire lower face.

The oblique folds extending from the lateral oral commissures to the edge of the mandible are called melomental folds. The deeper they become, the more negative the resulting facial expression. During the movements of speech and communication, the lateral oral commissures also depress more because of the action of depressor anguli oris and the pars facialis of the platysma.

The combination of the injection of BOTOX into the depressor anguli oris and mentalis and platysma removes the muscular depressor action

of the lower face. The lateral oral commissures elevate to a more relaxed neutral position and the dimpling action of mentalis on the chin is softened. When the mouth corners are really depressed, injection of the platysma as well is very helpful in allowing the perioral region to elevate.

BOTOX alone however, will not give the final esthetic result; adding soft tissue augmentation to buttress the mouth corners and the prejowl sulcus (FIG. 9a,b) gives a very youthful appearance (37,38).

Many subjects wish also to have their vertical lip rhytides addressed. We find that the injection of 4–5 units of BOTOX in the upper lip, 3 units in the lower lip and biodegradable filler injection

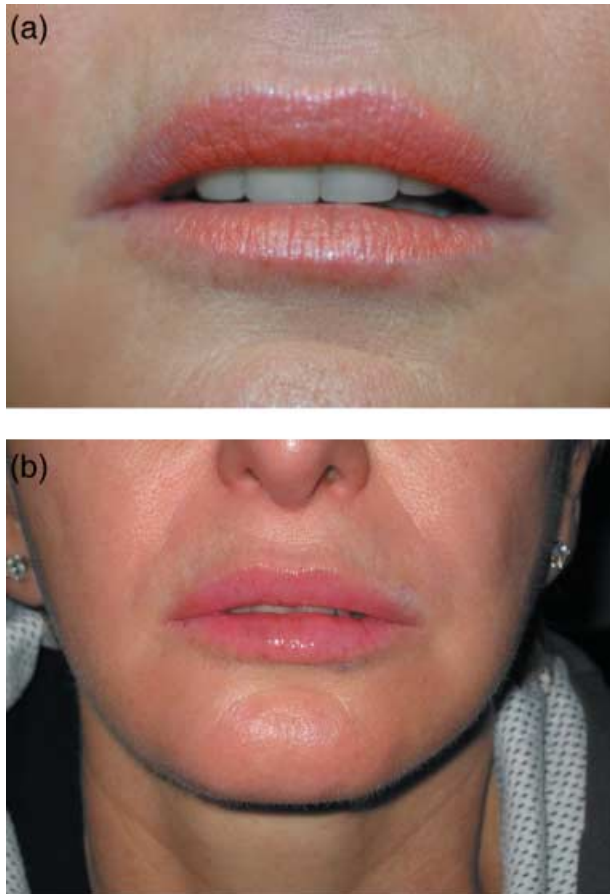

FIG. 10. (a) Pre-BTX-A to orbicularis oris and depressor anguli oris and mentalis and NASHA filler to the lips. (b) Appearance post BTX-A and NASHA filler.

gives a superb eversion of the upper lip so that the ski-tip morphology of the G-K point is restored. The gloss zone of the lower lip is also enhanced (FIG. 10a,b) (33,39,40).

Resetting contours in the cervical region

In our experience, treating horizontal necklace lines with BOTOX alone is not as successful as treating with BOTOX and adding treatment within the lines using Restylane Touch™.

In addition, many subjects prefer to have the vertical platysmal bands treated with BTX-A and the submental region softened with filler.

Summary

Cosmetic use of BTX-A had set a new gold standard for esthetic treatment success. The use of

intradermal and subcutaneous volumizing fillers has also raised the esthetic bar. Treatment with both modalities together gives an enhanced esthetic benefit and allows also for increased longevity of the result. As with any of the new technological innovations currently available, understanding of the differing properties of the agents used and education in optimal technique is essential to clinical and aesthetic success.

References

1. de Pedroza LV. Fat transplantation to the buttocks and legs for aesthetic enhancement or correction of deformities: long-term results of large volumes of fat transplant. *Dermatol Surg* 2000; **26**: 1145–1149.
2. Neuber F. Fettransplantation. *Chir Kongr Verhandl Dsch Gesellch Chir* 1893; **22**.
3. Naoum C, Dasiou-Plakida D. Dermal filler materials and botulinum toxin. *Int J Dermatol* 2001; **40**: 609–621.
4. Klein AW. Skin filling. Collagen and other injectables of the skin. *Dermatol Clin* 2001; **19**: 491–508, ix.
5. de Maio M. The minimal approach: an innovation in facial cosmetic procedures. *Aesthetic Plast Surg* 2004; **28**: 295–300.
6. Klein AW, Wexler P, Carruthers A, Carruthers J. Treatment of facial furrows and rhytides. *Dermatol Clin* 1997; **15**: 595–607.
7. Connor MS, Karlis V, Ghali GE. Management of the aging forehead: a review. *Oral Surg Oral Med Oral Pathol Oral Radiol Endod* 2003; **95**: 642–648.
8. Manaloto RM, Alster TS. Periorbital rejuvenation: a review of dermatologic treatments. *Dermatol Surg* 1999; **25**: 1–9.
9. Carruthers J, Carruthers A. Adjunctive botulinum toxin type A: fillers and light-based therapies. *Int Ophthalmol Clin* 2005; **45**: 143–151.
10. Brown LH, Frank PJ. What's new in fillers? *J Drugs Dermatol* 2003; **2**: 250–253.
11. Carruthers J, Carruthers A, Maberley D. Deep resting glabellar rhytides respond to BTX-A and Hylan B. *Dermatol Surg* 2003; **29**: 539–544.
12. Lowe NJ. Arterial embolization caused by injection of hyaluronic acid (Restylane). *Br J Dermatol* 2003; **148**: 379; author reply 379–380.
13. Schanz S, Schippert W, Ulmer A, Rassner G, Fierlbeck G. Arterial embolization caused by injection of hyaluronic acid (Restylane). *Br J Dermatol* 2002; **146**: 928–929.
14. Scott AB. Botulinum toxin injection into extraocular muscles as an alternative to strabismus surgery. *Ophthalmology* 1980; **87**: 1044–1049.
15. Carruthers A, Carruthers J. Botulinum toxin type A. *J Am Acad Dermatol* 2005; **53**: 284–290.
16. Carruthers J, Carruthers A. BOTOX: beyond wrinkles. *Clin Dermatol* 2004; **22**: 89–93.
17. Carruthers J, Stubbs HA. Botulinum toxin for benign essential blepharospasm, hemifacial spasm and age-related lower eyelid entropion. *Can J Neurol Sci* 1987; **14**: 42–45.
18. Carruthers JD, Carruthers JA. Treatment of glabellar frown lines with *Clostridium botulinum*-A exotoxin. *J Dermatol Surg Oncol* 1992; **18**: 17–21.
19. Kaltreider SA, Kennedy RH, Woog JJ, Bradley EA, Custer PL, Meyer DR. Cosmetic oculo-facial applications of botulinum toxin: a report by the American Academy of Ophthalmology. *Ophthalmology* 2005; **112**: 1159–1167.

20. Sposito MM. New indications for botulinum toxin type A in cosmetics: mouth and neck. *Plast Reconstr Surg* 2002; **110**: 601–611; discussion 612–603.
21. Flynn TC, Carruthers JA, Carruthers JA. Botulinum-A toxin treatment of the lower eyelid improves infraorbital rhytides and widens the eye. *Dermatol Surg* 2001; **27**: 703–708.
22. Hexsel D, Dal'forno T. Type A botulinum toxin in the upper aspect of the face. *Clin Dermatol* 2003; **21**: 488–497.
23. Frampton JE, Easthope SE. Botulinum toxin A (BOTOX Cosmetic): a review of its use in the treatment of glabellar frown lines. *Am J Clin Dermatol* 2003; **4**: 709–725.
24. Ferreira MC, Salles AG, Gimenez R, Soares MF. Complications with the use of botulinum toxin type A in facial rejuvenation: report of 8 cases. *Aesthetic Plast Surg* 2004; **28**: 441–444.
25. Fagien S, Brandt FS. Primary and adjunctive use of botulinum toxin type A (BOTOX) in facial aesthetic surgery: beyond the glabella. *Clin Plast Surg* 2001; **28**: 127–148.
26. Kher U. Beyond BOTOX. *Time* 2003; **161**: 58–59.
27. Carruthers J, Fagien S, Matarasso SL. Consensus recommendations on the use of botulinum toxin type A in facial aesthetics. *Plast Reconstr Surg* 2004; **114**: 1S–22S.
28. Carruthers JD, Lowe NJ, Menter MA, et al. Double-blind, placebo-controlled study of the safety and efficacy of botulinum toxin type A for patients with glabellar lines. *Plast Reconstr Surg* 2003; **112**: 1089–1098.
29. Carruthers A, Carruthers JDA, Lowe NJ, Menter A, Gibson J. One-year randomized two period study of the safety and efficacy of the treatment of glabellar lines with botulinum-A exotoxin. *J Clin Res* 2004; **7**: 1–20.
30. Carruthers J, Carruthers A, Maberley D. Advances in the use of botulinum toxin “deep resting glabellar rhytides respond to BTX-A and Hylan B.” *Dermatol Surg* 2003; **29**, 5: 539–544.
31. Carruthers J, Carruthers A. “A prospective, randomized, parallel group study analyzing the effect of BTX-A (BOTOX) and nonanimal-sourced hyaluronic acid (NASHA, Restylane) in combination compared with NASHA (Restylane) alone in severe glabellar rhytides in adult female subjects: treatment of severe glabellar rhytides with a hyaluronic acid derivative compared with the derivative and BTX-A.” *Dermatol Surg* 2003; **29**: 802–809.
32. Huilgol SC, Carruthers A, Carruthers JDA. Raising eyebrows with botulinum toxin. *Dermatol Surg* 1999; **25**: 373–376.
33. Carruthers JDA, Carruthers JA. Facial sculpting and tissue augmentation. *Dermatol Surg* 2005; **31**: 1604–1612.
34. Carruthers A, Carruthers J, Cohen J. A prospective double-blind, randomized, parallel group, dose-ranging study of botulinum toxin type A in female subjects with horizontal forehead rhytides. *Dermatol Surg* 2003; **29**: 461–467.
35. Flynn TC, Carruthers A, Carruthers JDA. Botulinum toxin A treatment of the lower eyelid improves infraorbital muscles and widens the eye. *Dermatol Surg* 2001; **27**: 703–708.
36. Carruthers JDA, Carruthers A. BOTOX use in the mid and lower face and neck. *Semin Cutan Med Surg* 2001; **20**: 85–92.
37. Carruthers A, Carruthers J. Aesthetic use of botulinum A exotoxin in the mid and lower face and neck. *Dermatol Surg* 2003; **29**: 468–476.
38. Dover JS, Carruthers JA, Carruthers JDA, Alam M. Clinical Use of Restylane™. *Skin Ther Lett* 2005; **10**: 5–7.
39. Carruthers J, Klein AW, Carruthers A, Glogau RG, Canfield D. Safety and efficacy of Restylane for improvement of mouth corners. *Dermatol Surg* 2005; **31**: 1–5.
40. Carruthers JDA, Fagien S, Matarasso SL, the BOTOX Consensus Group. Consensus recommendations on the use of botulinum toxin A in facial aesthetics. *Plast Reconstr Surg* 2004; **114**: 1S–22S. Review.